Journal of
Cardiology & Cardiovascular
Surgery

Case Report

DOI: 10.51271/JCCVS-0082

Wire-based percutaneous balloon mitral valvuloplasty after failed conventional valve crossing: a case report

Mehmet Ali Gelen*, Mehdi Karasu
Department of Cardiology, Elazığ Fethi Sekin City Hospital, Elazığ, Turkiye

Cite this article as: Gelen MA, Karasu M. Wire-based percutaneous balloon mitral valvuloplasty after failed conventional valve crossing: a case report. *J Cardiol Cardiovasc Surg.* 2026;4(3):69-71. doi:10.51271/JCCVS-0082

***Corresponding Author:** Mehmet Ali Gelen, maligelen4723@gmail.com

Received: 17.08.2026 ◆ **Accepted**: 28.09.2026 ◆ **Published**: 30.09.2026

ABSTRACT

Percutaneous balloon mitral valvuloplasty (PBMV), an important treatment for rheumatic mitral stenosis (MS), can be technically challenging in cases with difficult anatomy. This article describes a new wire-based PBMV technique involving the advancement of an Inoue balloon over a pre-shaped rigid 0.035-inch wire. The procedure begins with a targeted transseptal puncture, followed by introduction of a steerable sheath into the left atrium and subsequent passage across the diseased mitral valve (MV), replacement with a preformed 0.035-inch stiff wire in the left ventricle, advancement and positioning of an appropriately sized Inoue balloon over the MV on the wire, and inflation of the balloon. This technique uses additional equipment such as a steerable sheath and a preformed 0.035-inch stiff wire, in addition to the standard Inoue balloon kit. This may make the technique more costly. Due to the rheumatic MS occurs less commonly, socioeconomically developed societies, the number of operators experienced in PBMV procedures is quite rare. PBMV can be performed safely and predictably on the wire using the approach described.

Keywords: Ballon valvuloplasty, rheumatic heart disease, mitral stenosis

INTRODUCTION

Percutaneous balloon mitral valvuloplasty (PBMV), an important treatment for rheumatic mitral stenosis (MS), can be technically challenging in cases with difficult anatomy. This article describes wire-based PBMV technique involving the advancement of an Inoue balloon over a pre-shaped rigid 0.035-inch wire. The procedure begins with a targeted transseptal puncture, followed by introduction of a steerable sheath into the left atrium and subsequent passage across the diseased mitral valve (MV), replacement with a preformed 0.035-inch stiff wire in the left ventricle (LV), advancement and positioning of an appropriately sized Inoue balloon over the MV on the wire, and inflation of the balloon. This technique uses additional equipment such as a steerable sheath and a preformed 0.035-inch stiff wire, in addition to the standard Inoue balloon kit. This may make the technique more costly. Due to the rheumatic MS occurs less commonly, socioeconomically developed societies, the number of operators experienced in PBMV procedures is quite rare. PBMV can be performed safely and predictably on the wire using the approach described.

The Inoue balloon, originally developed by Toray Medical, has served as the reference technique for PBMV for many years, thanks to its self-positioning design, stepwise and adjustable diameter feature, and rapid inflation-deflation mechanism.[1] Proper transseptal puncture and safe entry into the LV are the most fundamental steps for the successful completion of PBMV.[2] In the classic Inoue technique, after appropriate transseptal puncture, a freely floating balloon is used to cross the diseased MV. However, even in experienced operators, entry into the LV can be technically difficult in challenging anatomical conditions (e.g., critical MS, severe subvalvular disease, thickening or bulging of the interatrial septum, or suboptimal transseptal puncture localization).[3] In these clinical scenarios, various modifications to the standard Inoue technique have been described (e.g., reverse loop technique, double balloon technique, vertical approach, and use of LV pressure as a guide at the left ventricular inflow tract).[4-6] An alternative technique based on guidewire support has been developed, in which the MV is crossed with a 0.025-inch coil wire and the Inoue catheter is advanced over this wire.[3] However, the inability of the 0.025-inch coil wire to provide adequate support for the Inoue balloon catheter particularly in anatomically complex cases, has prevented its establishment as a routine technique.

The prevalence of rheumatic MS and the procedural volume of PBMV remain low, even in high-income countries; consequently, operators may be unable to acquire sufficient experience with these alternative techniques. Experience with balloon-expandable valves in transcatheter MV replacement (TMVR), particularly for degenerated surgical bioprostheses or annuloplasty rings, is relatively well established. In this report, we present a step-by-step demonstration of a wire-based PBMV technique using the Inoue balloon, following

This work is licensed under a Creative Commons Attribution-NonCommercial-NoDerivatives 4.0 International License.

procedural steps analogous to those employed in TMVR interventions.

CASE REPORT

A 55-year-old female had NYHA functional class III heart failure symptoms. She had a history of rheumatic fever during childhood at the age of 10 years. On clinical examination, the first heart sound (S1) was notably loud and a diastolic rumbling murmur. Electrocardiography demonstrated atrial flutter (**Figure 1**). Transthoracic echocardiography (TTE) showed preserved left ventricular and right ventricular systolic function, along with marked biatrial enlargement. With the heart rate measured at 100 beats per minute, severe rheumatic MS was present, with a mean MV gradient of 12 mmHg. The MV area was measured as 1.1 cm^2 according to measurements obtained with the pressure half-time method and 0.9 cm^2 by the continuity equation. Only trivial mitral regurgitation was observed.

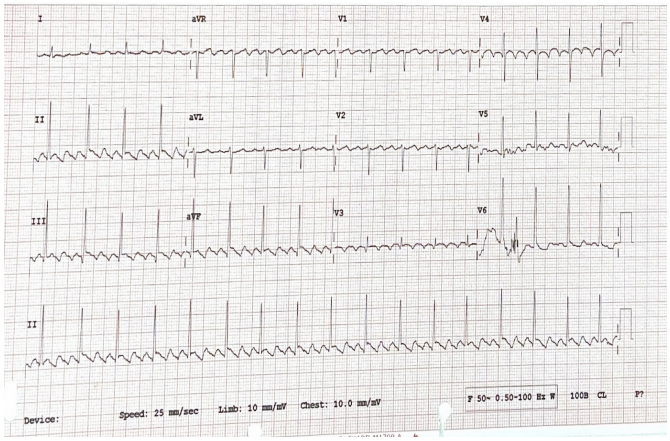

Figure 1. Atrial flutter

Transesophageal echocardiography (TEE) revealed a Wilkins score of 7, characterized by restricted leaflet motion predominantly at the leaflet bases during diastole, leaflet edge thickening, minimal subvalvular involvement, and increased echogenicity confined to a single area involving the anteromedial commissure. Assessment revealed an absence of thrombus in the left atrial chamber and appendage. Laboratory testing was largely normal, although N-terminal pro-B-type natriuretic peptide was elevated to 846 pg/ml. PBMV was planned for the patient. However, the MV could not be crossed using the classic Inoue technique. As an alternative, PBMV was planned using the Inoue balloon with a new wire-based technique.

Process Stages

The intervention was carried out with the patient under conscious sedation and TTE guidance. A 6-F pigtail catheter, inserted through right femoral arterial access, was positioned at the noncoronary aortic cusp to support transseptal puncture. A 16-F sheath was inserted through the right femoral vein. A VersaCross sheath (Boston Scientific) was then advanced through the 16-F sheath over a 0.032-inch guidewire into the left innominate vein (**Figure 2**). Subsequently, a transseptal puncture was used in the posterior position under TTE and fluoroscopic guidance. The VersaCross wire was guided into the left upper pulmonary vein. Following septostomy, a 14-F septal dilator was used over the VersaCross wire to dilate the left upper pulmonary vein. The medium-curvature steerable Agilis sheath (Abbott Vascular) was placed in the left atrium over the VersaCross wire. The wire and sheath dilator were subsequently removed. A standard 0.035-inch J-wire and a 6-F pigtail catheter were delivered to the left atrium with support from the Agilis sheath. Under TTE and fluoroscopic guidance, the steerable Agilis sheath was oriented toward the MV orifice, allowing the valve to be traversed with a pigtail catheter. A pre-shaped Safari XS wire (Boston Scientific) was then positioned to the LV apex. The pigtail catheter and Agilis sheath were subsequently removed. A 26 mm Inoue balloon was prepared to a maximum inflation size of 26 mm using standard technique (patient height: 160 cm). We then reloaded the balloon onto the Safari XS wire. The Inoue balloon was then inserted through the sheath and advanced through the septostomy and diseased MV in a tapered configuration to facilitate easier passage. The balloon was then returned to a dumbbell configuration on the Safari XS wire and inflated (**Figure 3**).

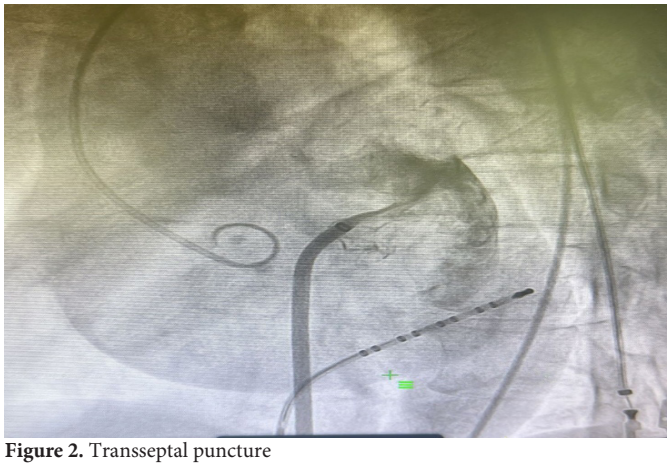

Figure 2. Transseptal puncture

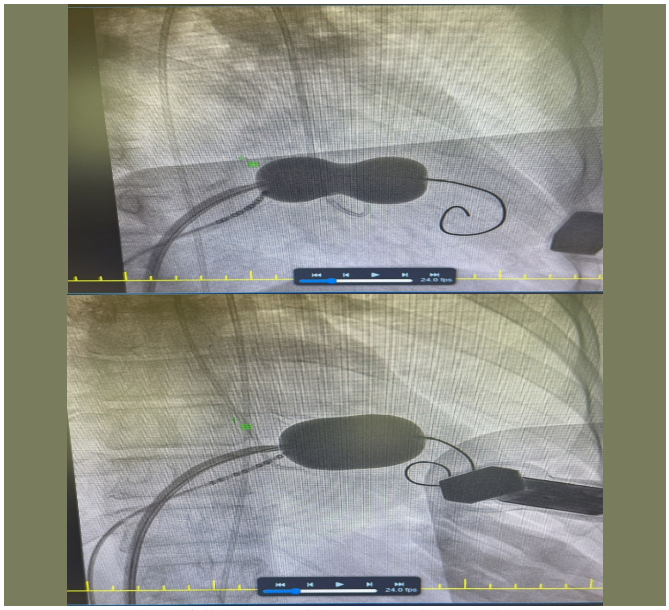

Figure 3. Partial and full dilation of the Inoue balloon catheter

Subsequently, PBMV was successfully performed in a standard manner by applying a single dilation via the wire. After the procedure, effective separation of the medial commissure, a marked increase in valve mobility, a decrease in the mean MV gradient to 4.5 mmHg by TTE (**Figure 4**), and no increase in the degree of mitral regurgitation were observed. Subsequently, the Inoue balloon was deflated. The pre-shaped

left ventricular (LV) wire was safely removed via the pigtail catheter and the venous sheath was removed to minimize the risk of MV and left ventricular damage.

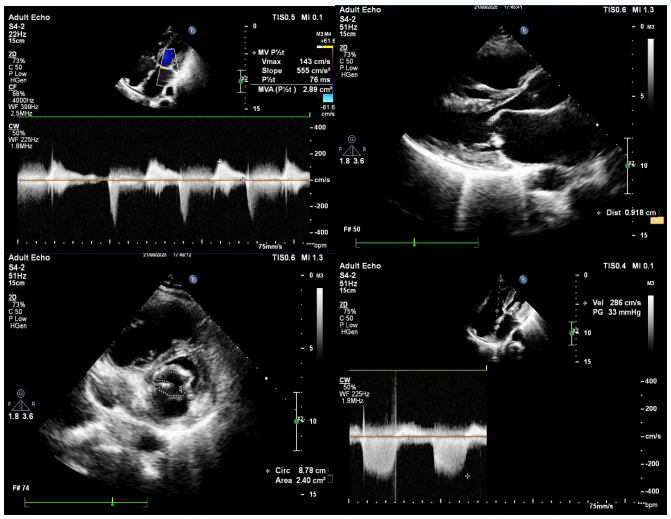

Figure 4. Parasternal long-axis view showing increased diastolic excursion and mobility of the anterior mitral leaflet. MV Doppler analysis demonstrates a mean MV gradient of 4.5 mmHg at a heart rate of 97 beats/min. The MV area was 2.89 cm² by the pressure half-time method. These echocardiographic images were obtained three months after PBMV

MV: Mitral valve, PBMV: Percutaneous balloon mitral valvuloplasty

A mean MV gradient of 5 mmHg was documented on post-procedural TTE when the heart rate was 94 beats per minute; the MV area was calculated as 1.8 cm² using the continuity equation and 2.0 cm² by pressure half-time assessment. The estimated systolic pressure of the right ventricle decreased from 50 mmHg before the procedure to 20 mmHg (**Figure 4**). The patient was discharged the next day without complications. Significant improvement in the patient's clinical symptoms was observed at the first- and third-month follow-ups.

DISCUSSION

Relative to the conventional Inoue technique, this approach requires additional devices, including a steerable Agilis sheath and a pre-shaped left ventricular wire, which may increase procedural costs and limit its routine use in resource-constrained settings. In the present case, the procedure was performed under conscious sedation with fluoroscopic and transthoracic echocardiographic guidance. The pre-shaped Safari XS wire was selected to provide stable support for balloon advancement; its position was monitored during the procedure, and it was removed through a pigtail catheter to reduce the risk of ventricular perforation, chordal entanglement, or mitral apparatus injury.

Alternative strategies have been described for technically demanding cases. In the reverse loop technique, a double loop is created in the left atrium by rotating the J-shaped stylet counterclockwise, positioning the Inoue balloon toward the MV orifice.[4] This approach may be useful in patients with marked left atrial dilatation, particularly after a low and anterior transseptal puncture.[7] Our case demonstrates the application of the previously described wire-based approach after conventional valve crossing failed. Because this report describes a single case, the safety and reproducibility of the approach require further evaluation.

CONCLUSION

This case illustrates the successful use of a previously described wire-based Inoue balloon technique after conventional MV crossing failed. A pre-shaped guidewire positioned in the LV provided support for balloon advancement, using procedural steps familiar from transcatheter MV interventions. Although the procedure was successful in this patient, its safety and reproducibility cannot be established from a single case.

ETHICAL DECLARATIONS

Informed Consent

Written informed consent was obtained from the patient included in this report. Signed consent forms are retained by the authors and are available upon request.

Peer Review Process

This report underwent external peer review.

Conflict of Interest

The authors declare no conflicts of interest.

Financial Disclosure

This case report did not receive any financial support.

Author Contributions

Concept: MAG, MK; Design: MAG, MK; Control: MAG, MK; Resources: MAG, MK; Materials: MAG, MK; Data Collection and/or Processing: MAG, MK; Analysis and/or Interpretation: MAG, MK; Literature Review: MAG, MK; Writing the Article: MAG, MK; Critical Review: MAG, MK.

REFERENCES

1. Nobuyoshi M, Arita T, Shirai S, et al. Percutaneous balloon mitral valvuloplasty: a review. *Circulation*. 2009;119(8):e211-e219. doi:10.1161/CIRCULATIONAHA.108.792952
2. Inoue K, Owaki T, Nakamura T, Kitamura F, Miyamoto N. Clinical application of transvenous mitral commissurotomy by a new balloon catheter. *J Thorac Cardiovasc Surg*. 1984;87(3):394-402.
3. Manjunath CN, Srinivasa KH, Patil CB, Venkatesh HV, Bhoopal TS, Dhanalakshmi C. Balloon mitral valvuloplasty: our experience with a modified technique of crossing the mitral valve in difficult cases. *Cathet Cardiovasc Diagn*. 1998;44(1):23-26. doi:10.1002/(sici)1097-0304(199805)44:1<23::aid-ccd6>3.0.co;2-9
4. Trehan V, Mehta V, Mukhopadhyay S, Yusuf J, Kaul UA. Difficult percutaneous transvenous mitral commissurotomy: a new technique for left atrium to left ventricular entry. *Indian Heart J*. 2004;56(2):158-162.
5. Hung JS, Lau KW. Vertical approach Ñ a modified method in balloon crossing of mitral valve in Inoue balloon mitral valvuloplasty. *J Invasive Cardiol*. 1998;10(9):548-550.
6. Safi AM, Kwan T, Clark LT. Successful percutaneous balloon mitral valvuloplasty using left ventricular pressure as a guide to cross the mitral valve-a case report. *Angiology*. 2000;51(1):83-86. doi:10.1177/000331970005100113
7. Gupta T, Barrett T, Dauerman HL, Lahoud RN. Novel wire-based technique for percutaneous balloon mitral valvuloplasty. *JACC Case Rep*. 2025;30(3):103130. doi:10.1016/j.jaccas.2024.103130